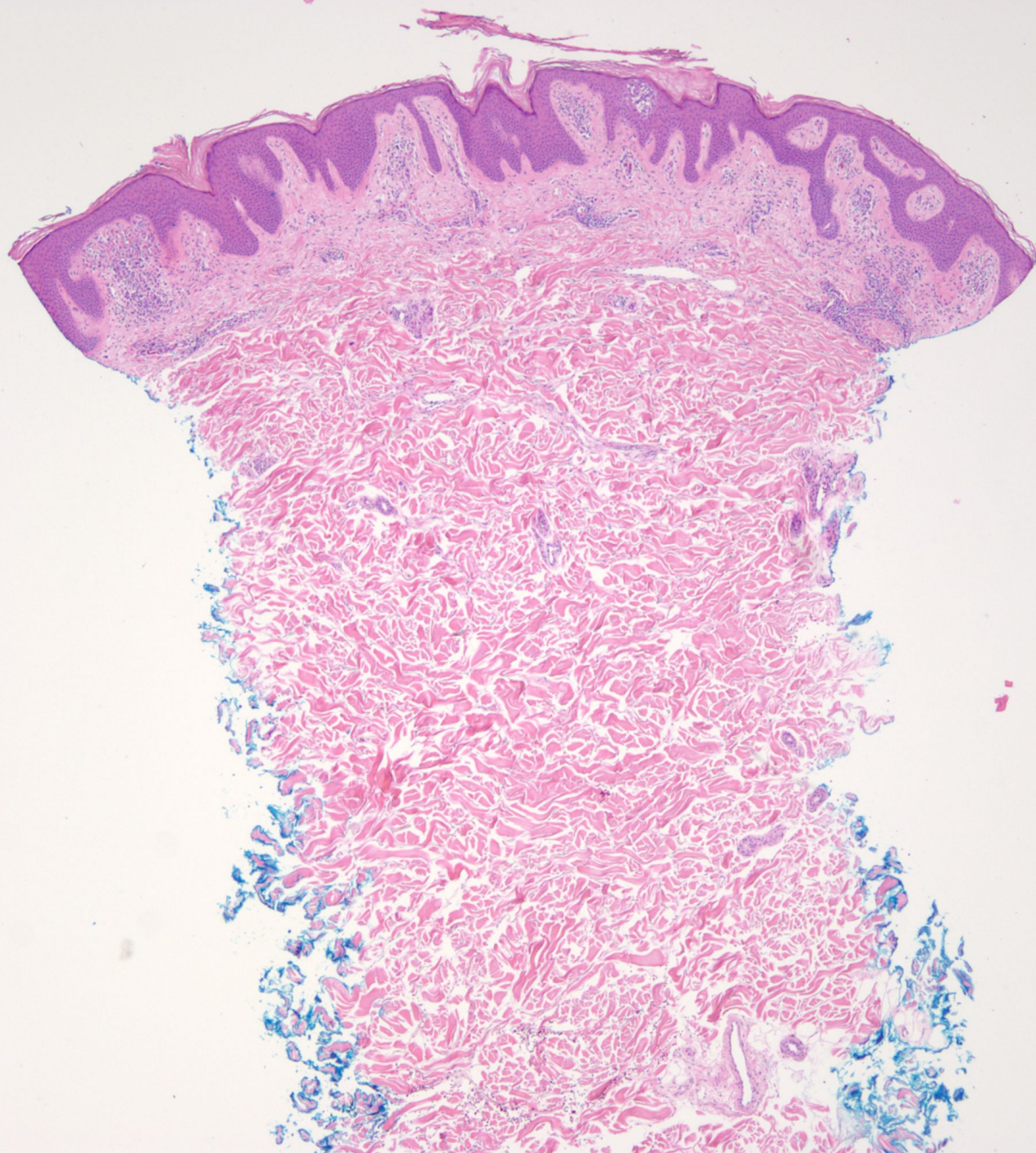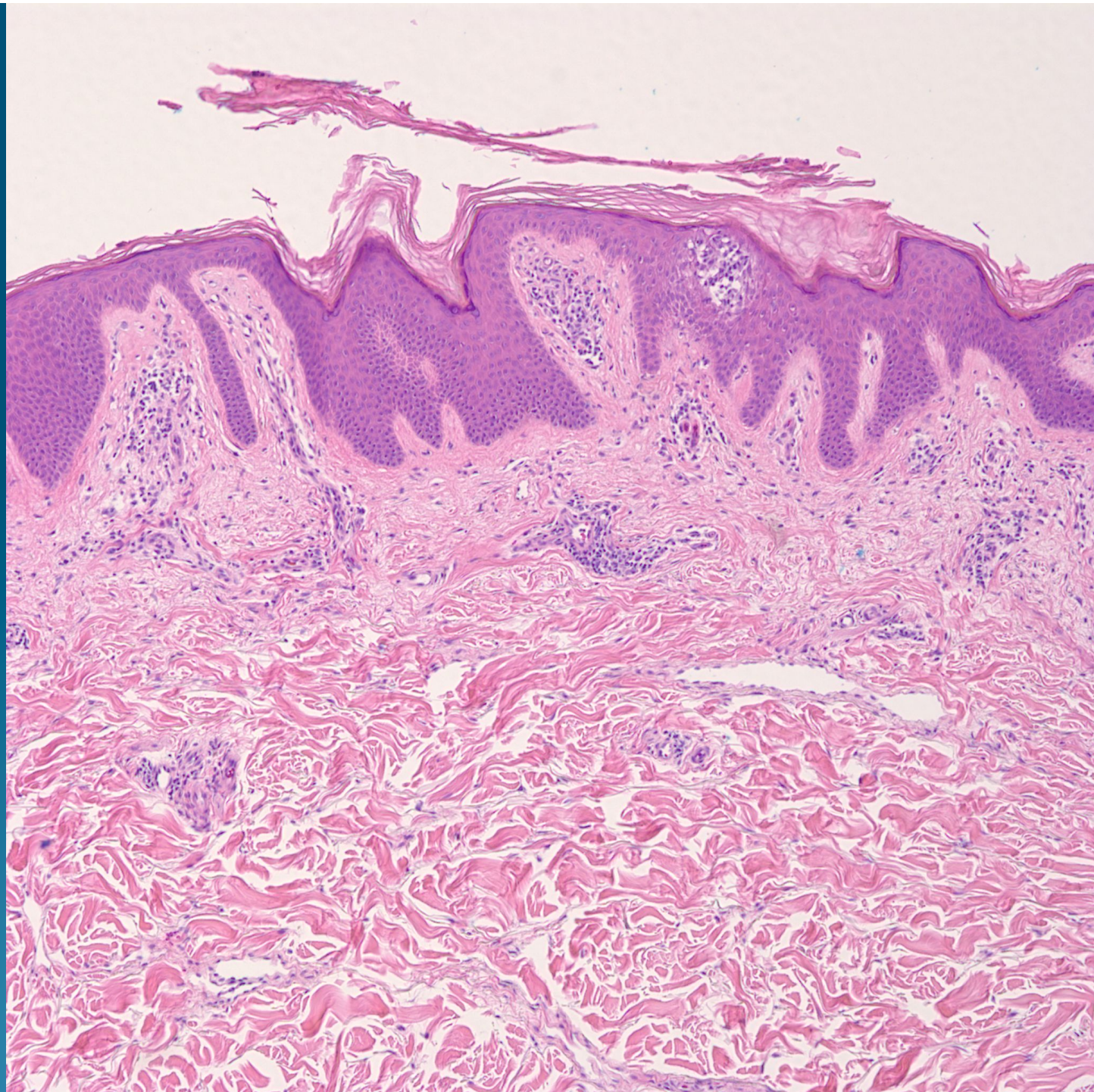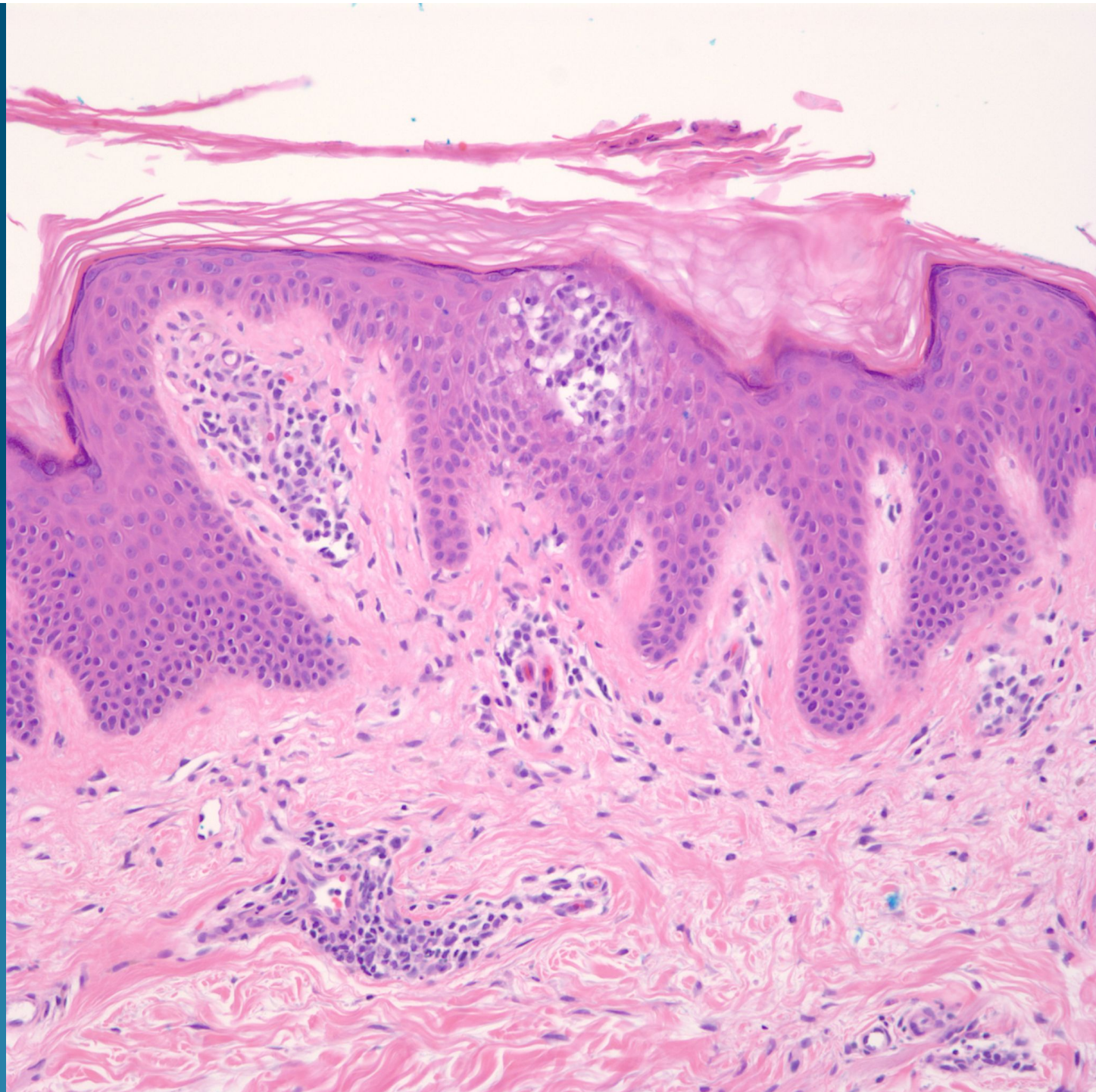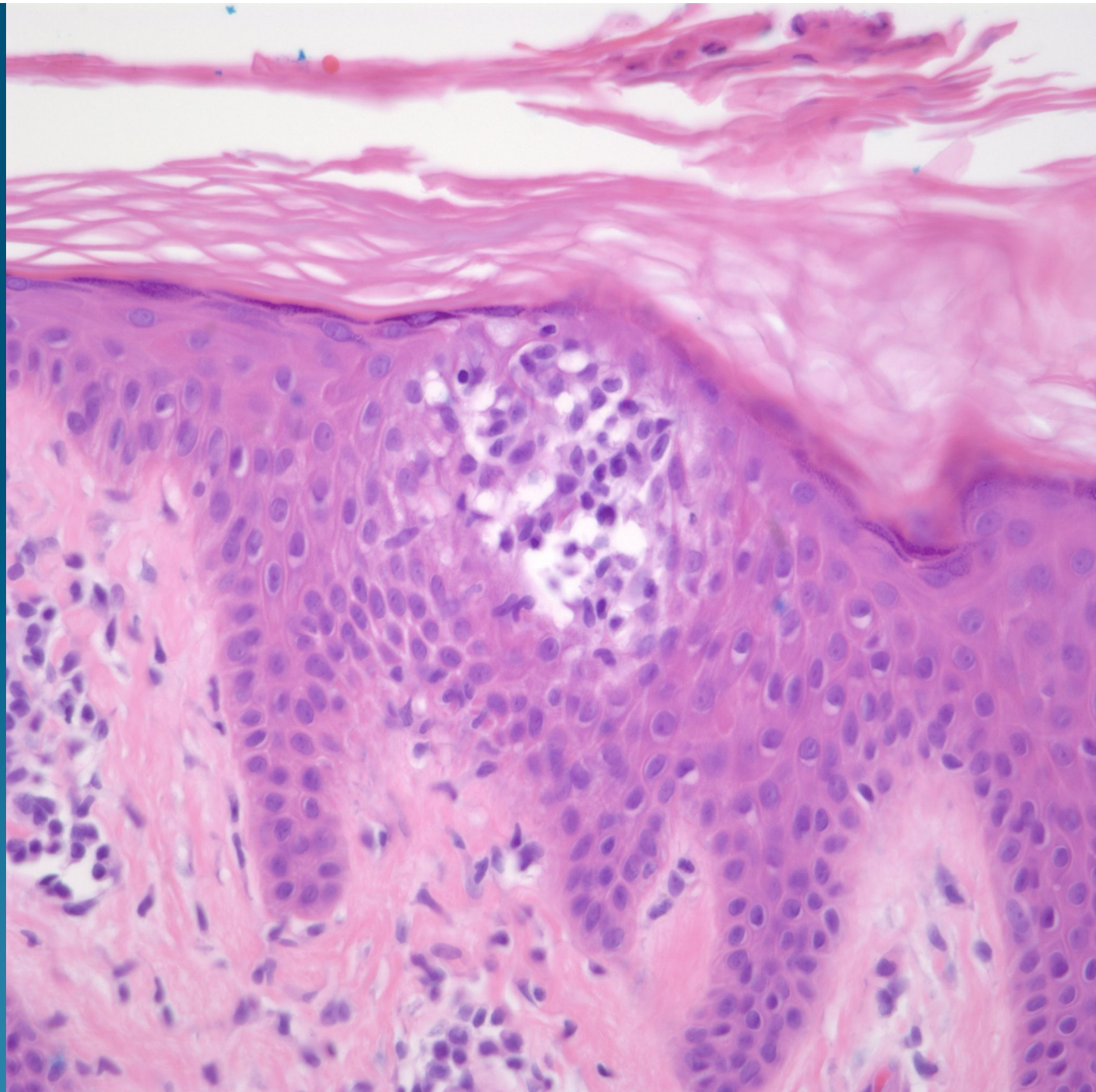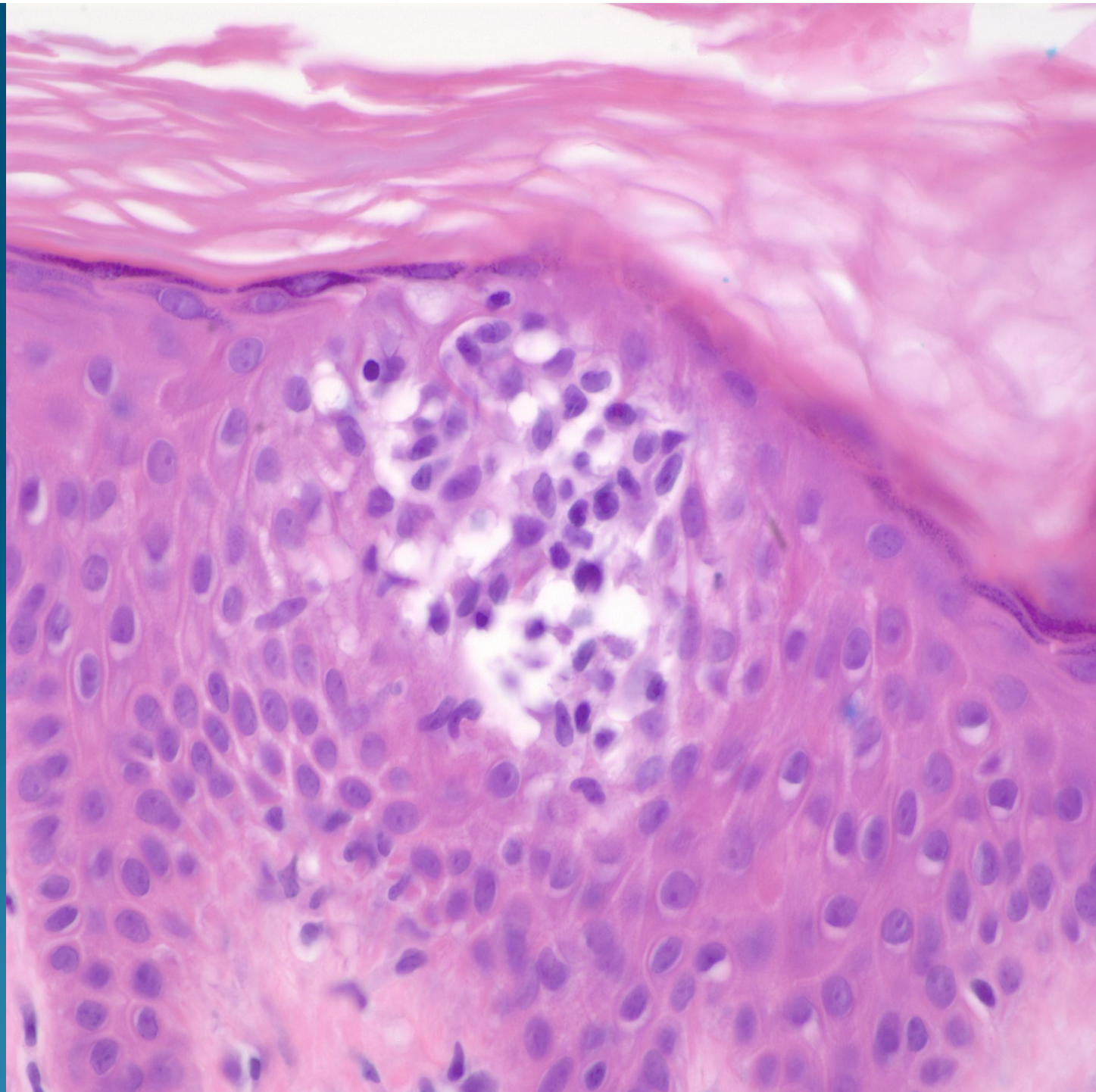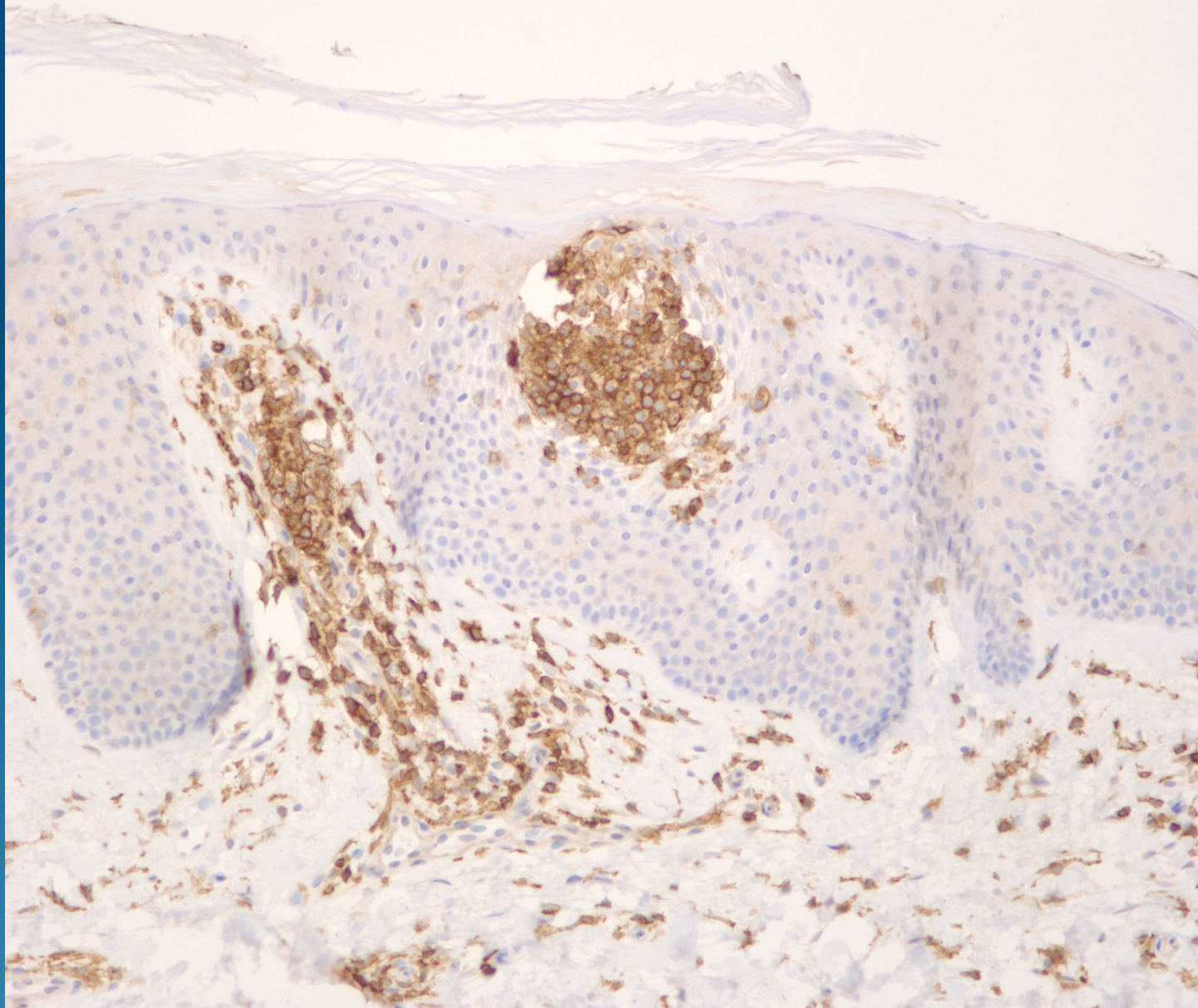
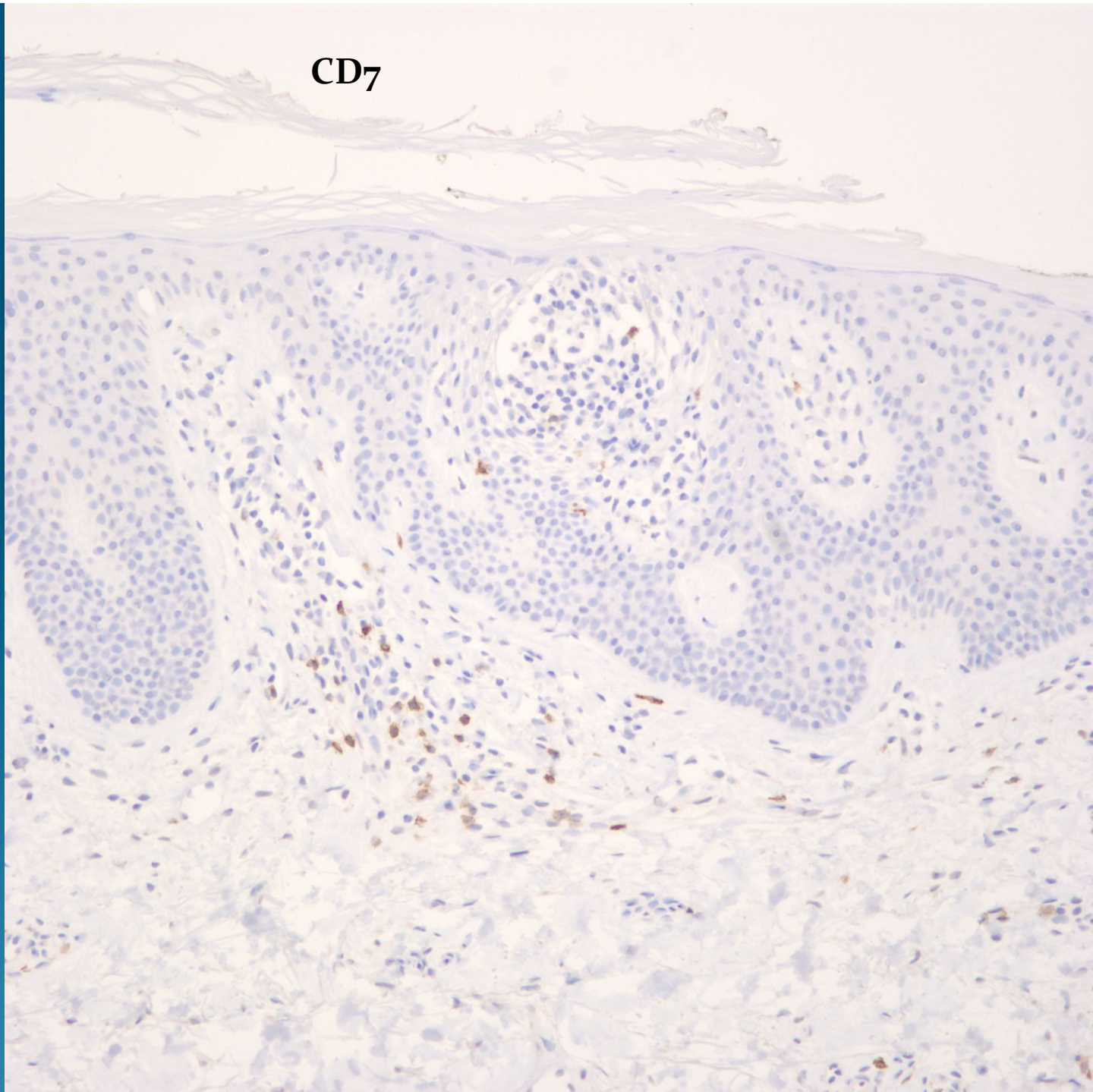


CD4



CD7

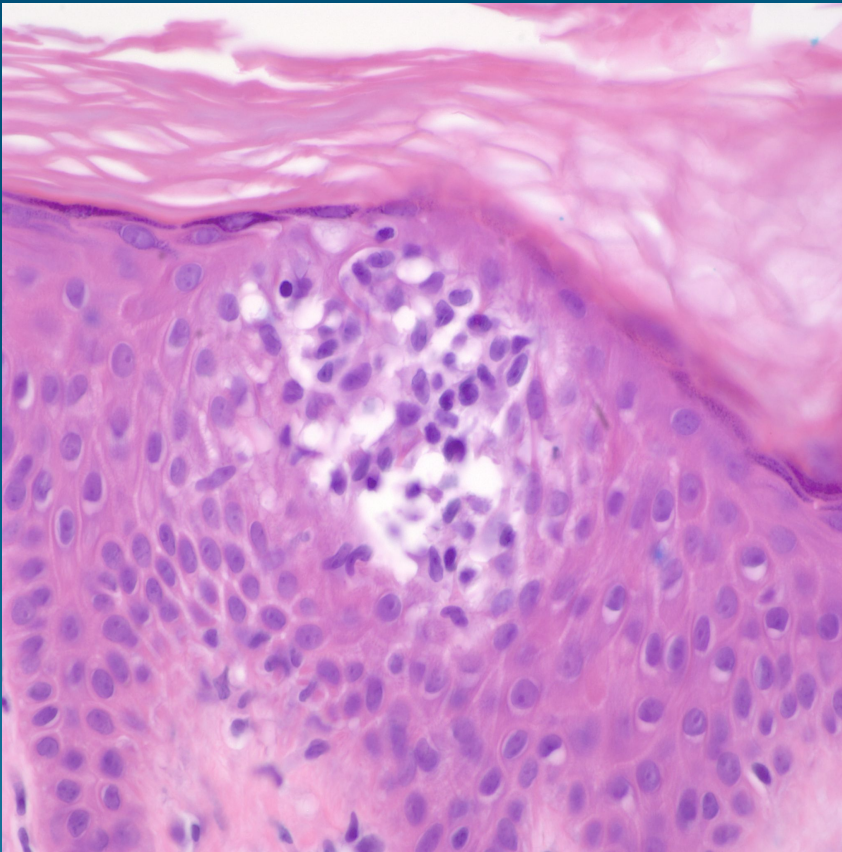


What is the best diagnosis?

- A. Langerhans cell histiocytosis
- B. Cutaneous Mastocytosis
- C. Anaplastic large cell lymphoma
- D. Chronic lymphocytic leukemia
- E. Mycosis fungoides

Mycosis fungoides

Pearls



- Atypical lymphocytes with hyperconvoluted nuclear contours and nuclear enlargement
- Pautrier microabscesses- intraepidermal collections of atypical lymphocytes with minimal spongiosis
- Confirm by CD4+ and usually CD5 and CD7 negative